

Comparison of Filling Agents for Lip Augmentation

Deborah S. Sarnoff, MD; Ritu Saini, MD; and Robert H. Gotkin, MD

The authors discuss various filling agents currently available that can be used to augment the lips, correct perioral rhytides, and enhance overall lip appearance. Fillers are compared and information provided about choosing the appropriate agent based on the needs of each patient to achieve the much coveted “pouty” look while avoiding hypercorrection. The authors posit that the goal for the upper lip is to create a form that harmonizes with the patient’s unique features, taking into account age and ethnicity; the goal for the lower lip is to create bulk, greater prominence, and projection of the vermilion. (*Aesthetic Surg J* 2008;28:556–563.)

In virtually all cultures since the beginning of recorded history, full lips have been associated with female youth, beauty, and voluptuousness. In youthful lips of white patients, for example, the ideal ratio of the upper to lower lip is 1:1.6 (Figure 1).¹ However, the properties of the lips change with age, resulting in lengthening of the cutaneous portion of the upper lip and the upper lip vermilion gradually losing volume and becoming thinner (Figure 2). Genetics, intrinsic aging, sun exposure, smoking, and repetitive pursing of the orbicularis oris produce angular, radial, and vertical “lipstick bleed lines” (Figure 3). Gravity, maxillo-mandibular bony resorption and further soft tissue volume loss at the oral commissures cause the commissures to turn downward in a perpetual frown, creating vertical geniomandibular lines which extend downward from the oral commissures and are commonly called “marionette lines” (Figure 4). In addition to this hard and soft tissue volume loss, the lip margin itself may become blunted with flattening of the philtrum columns and loss of projection of the cupid’s bow (Figure 5).^{2–4}

There are many products available to correct the signs of aging in the lips, including permanent and nonpermanent dermal fillers, implants, neurotoxins, lasers, and micropigmentation. The most popular and commonly used lip enhancers are the dermal fillers.

A wide range of techniques are used by physicians to maximize results and minimize patient discomfort and potential adverse outcomes when injecting fillers. There is no single formula for successful lip augmentation; to a large degree, it is an art. Achieving a natural look

requires a thorough understanding of anatomy, available materials, and technique. “Sausage” or “duck” lips do not occur from mere overcorrection, but also from a poor understanding of the delicate contours of lip anatomy (Figure 6). In general, the objective in treating the upper lip is to create a form that aesthetically harmonizes with the patient’s unique facial features and takes into account the age and ethnic background of the patient. In treating the lower lip, the goal is to create bulk, greater prominence and projection of the vermilion. It is the responsibility of the physician to educate the patient regarding normal lip proportions in order to discourage the concept of a bizarre, cartoon-like appearance.

TECHNIQUE

A variety of products may be used to augment the lips, a facial feature that easily conveys telltale signs of aging. Regardless of the modality chosen, the physician must have not only anatomic knowledge and technical skill but also the aesthetic sense to create natural-looking, youthful, and sensuous lips. Every lip is different, and there is no set formula to ensure desired results. There are, however, some basic premises to follow gleaned from the senior authors’ (DSS and RHG) experience:

(1) Avoid obliteration of the cupid’s bow and creation of the “sausage” or “duck” lip (Figure 6).

(2) Keep in mind the areas that have a natural prominence or protuberance: 2 tubercles just lateral to the midline on the lower lip, 2 tubercles laterally in the upper lip, and 1 tubercle in the midline on the upper lip (Figure 7). Maintaining these landmarks will help to achieve the frequently coveted “pouty” look.

(3) Massage after injecting to help attain desired shape and structure.

(4) Be aware of medications that may predispose patients to ecchymosis (aspirin, warfarin, nonsteroidal anti-inflammatory drugs, and even Vitamin E, herbal sup-

Dr. Sarnoff is Associate Clinical Professor, Ronald O. Perleman Department of Dermatology, New York University School of Medicine, New York, NY. Dr. Saini is a Fellow in Mohs Surgery. Dr. Gotkin is Adjunct Surgeon at New York Eye & Ear Infirmary, New York, NY.

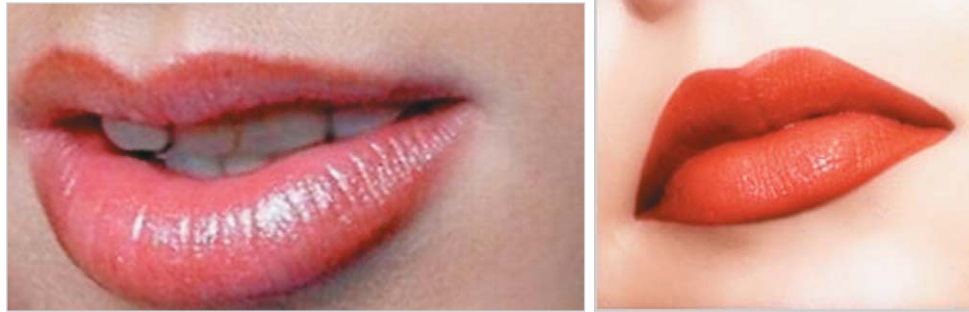


Figure 1. In youthful lips of white patients, the ideal ratio of the upper to the lower lip is 1:1.6.

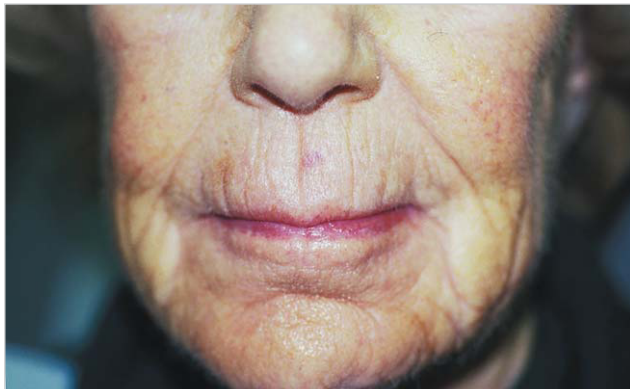

Figure 2. Thinning and loss of vermilion volume and lengthening of the cutaneous portion of the upper lip with age.

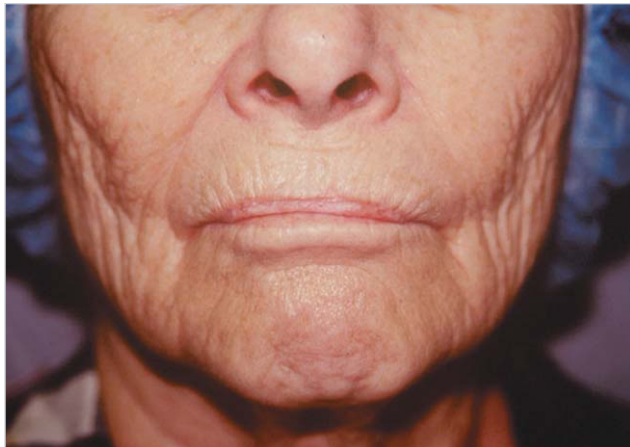

Figure 3. Angular, radial, and vertical “lipstick bleed lines” are often the result of genetics, intrinsic aging, sun exposure, smoking, and repetitive pursing of the orbicularis oris muscle.

plements and other preparations not approved by the US Food and Drug Administration (FDA).

(5) Inject the upper lip first so that postinjection swelling will not prevent maintenance of the correct anatomic proportions between upper and lower lips.

(6) Pay careful attention to the patient’s request, making sure it is reasonable. Unrealistic expectations may be a sign of body dysmorphic disorder, in which case treatment refusal may be appropriate.

FILLER SELECTION

Successful lip augmentation is highly dependent on choice of filler material, which is based on what the physician and patient are attempting to accomplish. There are 5 main elements of lip rejuvenation to consider:

(1) Enhancement of the white roll, which is achieved by injecting along the vermilion–cutaneous junction to prevent “lipstick bleeding” into the vertical rhytides of the lip.

(2) Volume augmentation of the body of the lip, which is accomplished by injecting into the vermilion and mucosa with the intention of producing larger, more robust lips. Injection may be in selected areas or throughout the lips.

(3) Correction of the vertical rhytides, which is achieved by injecting perpendicularly to the long axis of the lip and parallel to the rhytides. These results can be further enhanced by the injection of a neuromodulator, such as botulinum toxin, to relax the dynamic action of the orbicularis oris muscle.

(4) Elevation of the oral commissures, which is achieved by placing filler in the most lateral aspect of the lower lip to provide support to the commissures. This effort can be supported by placement of a neurotoxin in the depressor anguli oris muscles.

(5) Enhancement of the philtrum columns of the upper lip, which is accomplished by superficial vertical injection of filler into each philtrum column. It is important to realize that the philtrum columns are not parallel to each other, but rather form an inverted “V” shape that narrows as it approaches the nostril sills and columella of the nose (Figure 8).⁵

Fillers may be segregated into several broad categories. Among the temporary biodegradable fillers are those derived from bovine collagen (Zyderm and Zyplast; Allergan, Irvine, CA), those derived from human collagen (Cosmoderm and Cosmoplast; Allergan), and one derived from porcine collagen (Evolve; ColBar LifeScience Ltd., Herzliya, Israel). There are fillers derived from avian hyaluronic acid (HA) (Hylaform and Hylaform Plus, Allergan) and many derived from bacterial or nonanimal stabilized HAs (NASHA), such as Restylane (Medicis, Scottsdale, AZ); Perlane (Medicis); Prevelle (Mentor,

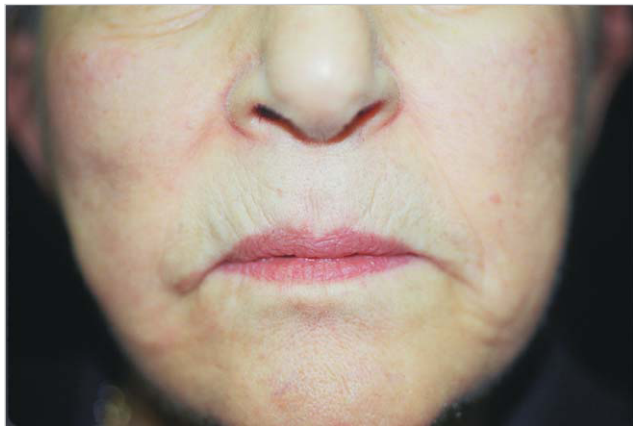

Figure 4. Gravity, maxillomandibular bony resorption, and further soft tissue volume loss at the oral commissures cause the commissures to turn downward in a perpetual frown.

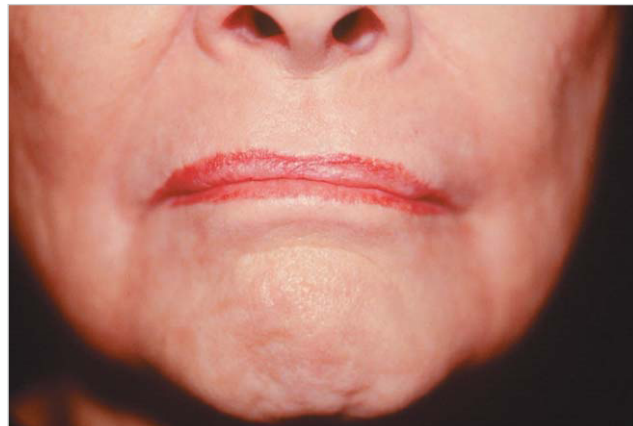

Figure 5. Vertical geniomandibular (“marionette”) lines extend downward from the oral commissures. Both hard and soft tissue volume loss cause the lip margin to become blunted with flattening of the philtrum columns and loss of projection of the cupid’s bow.

Santa Barbara, CA); and the Juvéderm (Allergan) family of products. Semipermanent fillers are stimulatory in nature and include calcium hydroxylapatite (Radiesse; BioForm, San Mateo, CA) and poly-L-lactic acid (Sculptra; Sanofi Aventis, Bridgewater, NJ). Stimulatory fillers stimulate or induce new collagen formation. Radiesse is a biphasic bioactivator; the calcium hydroxylapatite microspheres (the stimulatory component) are suspended in a carboxymethylcellulose gel. The latter gives immediate volume correction, but is more rapidly metabolized. The calcium hydroxylapatite microspheres remain after the gel is metabolized and become surrounded by new collagen bundles; these are the “stimulatory” component of the product. Sculptra is a monophasic stimulatory filler; it gives no immediate volume enhancement, but promotes neocollagenesis and dermal thickening over time. Sculptra requires several treatments to obtain the desired clinical result. The stimulatory fillers are more robust, generally require deeper placement, and seem to have a higher incidence of nodules when placed in the lips. Therefore, they are not recommended for lip augmentation.

Among the permanent fillers are polymethylmethacrylate (PMMA) beads suspended in a bovine collagen gel (ArteFill; Artes Medical, San Diego, CA;

another biphasic filler); silicone (Silikon 1000; Alcon Labs, Fort Worth, TX); and Adatosil 5000 (Bausch & Lomb, Rochester, NY). These permanent fillers are also prone to nodule formation and should be used only by experienced injectors. Autologous fat, surgical lip implants, botulinum toxin A, ablative and nonablative skin resurfacing, ablative and nonablative fractional skin resurfacing, and micropigmentation are all adjunctive therapies that may be used to augment or rejuvenate the lips. We will limit our discussion, however, to those dermal and subdermal fillers that may be used in the lips (Table 1).

Collagen

The earliest fillers approved by the FDA were derived from bovine collagen. Zyderm and Zyplast were introduced to the cosmetic surgery market in the early 1980s and became the standard against which all other injectable fillers were measured.⁶ Because these products are derived from bovine collagen, they require a skin test to determine allergic cross-reactivity; this necessitates a wait of at least 4 weeks before lip implantation. Human-derived collagen, obtained from neonatal foreskin (Cosmoderm and Cosmoplast) was developed and approved by the FDA in 2003. The advantages of these

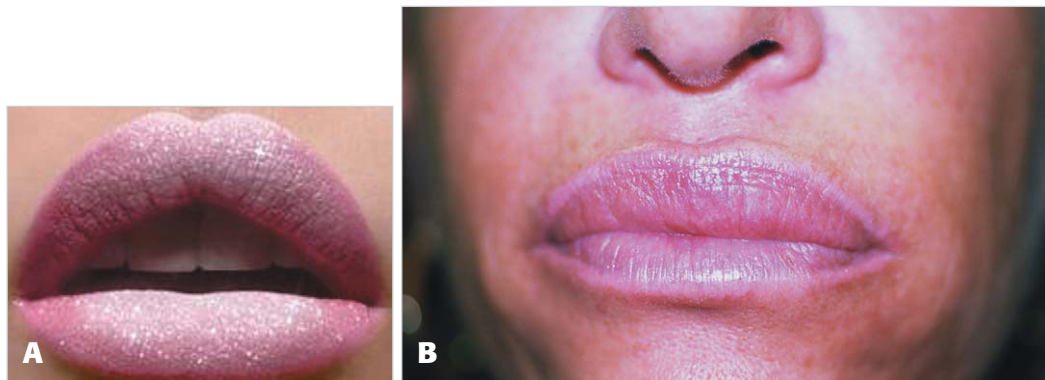

Figure 6. A. “Sausage” or “duck” lips occur from overcorrection, but also from a poor understanding of the delicate contours of lip anatomy. **B.** Avoid obliteration of the cupid’s bow and creation of the “sausage” or “duck” lip.

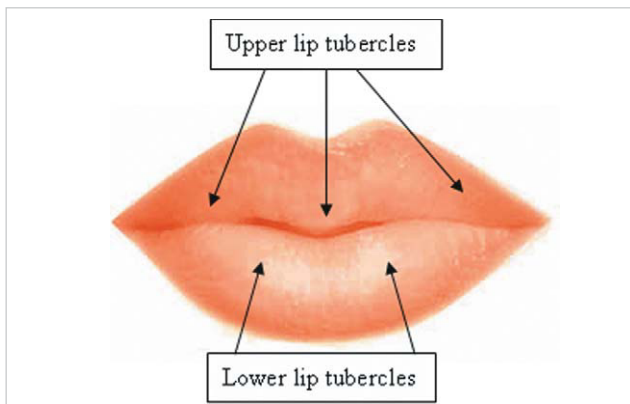


Figure 7. Tubercles of the upper and lower lips are interlaced and should be enhanced during lip augmentation.

products are that they do not require an allergy skin test and they were approved for restoration of the lip border.⁷

The distinction between both fillers in each class is that Zyplast and Cosmoplast are cross-linked and therefore useful for moderate to deep lines. With respect to the lips, they are very useful for placement into the vermillion-cutaneous junction of the upper and lower lips. In the senior authors' (D.S.S., R.H.G.) experience, implantation just below the vermillion border will create a sharply defined margin generally requiring only 2 entry sites on either side of the lip. Accentuation of the philtrum columns and cupid's bow is usually achieved in separate, precise injections. Zyderm and Cosmoderm are non-cross-linked and are ideal for upper lip rhytides. They can be injected superficially without the risk of forming nodules or creating the bluish discoloration (Tyndall effect) frequently seen with the HA fillers. A distinct advantage of these 4 collagen fillers is their off the shelf admixture with lidocaine. A limitation with all of the collagen products, however, is that the average duration is only about 3 months, compared to HAs that generally last an average of 4 to 12 months.⁸ Despite this, there is still a use for collagen in the lips, because it appears to provide structure with minimal swelling, bruising, erythema, and downtime—characteristics more commonly seen with the HA products.⁹

Hyaluronic Acid

The next group of fillers is derived from HA, a naturally occurring substance found in the connective tissues that cushions and lubricates. Because HAs are hydrophilic, they attract water from surrounding tissues, further augmenting soft tissue volume beyond what is expected from product implantation alone. For this reason, HA fillers are often excellent choices for enhancing lip volume. Among these fillers is Restylane, a partially cross-linked NASHA that is produced by fermentation from cultured *Streptococcus* bacteria. Restylane was approved by the FDA in 2003 for the treatment of moderate to severe facial wrinkles and folds.¹⁰ Perlane is a more robust, larger particle size form of HA compared with Restylane and is indicated for deeper implantation. It is

also approved by the FDA for the correction of moderate to severe facial wrinkles and folds and can thus provide good structure and long-lasting correction when injected into the lips. Injecting a small amount into the oral commissures and the lateral aspect of the lower lip can help to achieve a more youthful appearance by elevating the corners of the mouth.

As previously mentioned, limitations of the nonanimal derived HAs are significant bruising, swelling, and erythema. Therefore, they would probably not be the filler of choice for someone with an important social event in the days immediately following injection.¹¹ These sequelae are even more evident in the lip, given a high degree of vascularity and tendency for edema. Although skin testing is not required for HAs, there have been reports of granulomatous and hypersensitivity reactions, including one associated with angioedema.¹²⁻¹⁴ Treatment of the nasolabial folds, albeit quite common, has also been complicated by 2 reported cases of embolization of the dorsal nasal artery.^{15,16} A unique complication from too-superficial implantation of HA fillers is a bluish appearance emanating from within the dermis as a result of the Tyndall effect.¹⁷ The Tyndall effect and formation of nodules (especially with the larger particle sized Perlane) are largely a result of improper product placement and lack of adequate massage, which further highlights that skill and technique are of paramount importance. Fortunately, the temporary nature of these materials and the accessibility of hyaluronidase to digest the product can alleviate these problems.

Another HA-derived filler is animal-based Hylaform (hylan-B gel). Approved by the FDA in April 2004 for injection into the mid to deep dermis for the correction of moderate to severe facial wrinkles and folds,¹⁸ Hylaform consists of high molecular weight cross-linked hyaluronan polysaccharide chains obtained from rooster combs. Hylaform Plus is simply formed from a larger mean HA gel particle and used to correct deeper lines and folds.¹⁹ Hylaform contrasts with Restylane and Perlane in that it is much "softer" and therefore an excellent filler for the body of the lip. There seems to be much less bruising associated with it, making it an excellent choice if the patient has to attend a social event shortly after treatment. The minimal bruising occurs because Hylaform is already saturated with water and is in equilibrium hydration before injection as opposed to Restylane and Perlane, which are below hydration equilibrium and thus absorb water after injection. Potential pitfalls with Hylaform are that because it is avian-derived, it is not a good choice in patients with an allergy to poultry and, just as with other HAs, there have been reports of granulomatous reactions.²⁰

Among the newer HA-derived fillers are Juvéderm Ultra and Juvéderm Ultra-Plus. Both were approved by the FDA in 2006 for the correction of nasolabial folds.²¹ Whereas Restylane contains 20 mg/mL of hyaluronan with a small uncross-linked proportion, Juvéderm Ultra is 24 mg/mL, of which 21.6 mg/mL is cross-linked, and the Ultra Plus vari-

Table 1. Comparison of common filling agents available in the United States

Product	Manufacturer	Active ingredient	Description	Duration	Skin test	Lidocaine
Zyderm I	Allergan	Bovine collagen	35 mg/mL	3 mos	Yes	Yes
Zyderm 2	Allergan	Bovine collagen	65 mg/mL	3 mos	Yes	Yes
Zyplast	Allergan	Bovine collagen	35 mg/mL, cross-linked with glutaraldehyde	3+ mos	Yes	Yes
Cosmoderm	Allergan	Human collagen	35 mg/mL	3 mos	No	Yes
Cosmoplast	Allergan	Human collagen	35 mg/mL, cross-linked with glutaraldehyde	3+ mos	No	Yes
Evolence, ^a Evolence Breeze ^a	ColBar LifeScience	Porcine collagen	35 mg/mL, cross-linked with ribose (glycation); free of telopeptides	≤12 mos	No	No
Restylane	Medicis	NASHA	20 mg/mL, 100,000 particles/mL; BDDE cross-linked	6 mos	No	No
Restylane Touch/Fine Line	Medicis	NASHA	500,000 particles/mL; BDDE cross-linked	6 mos	No	No
Perlane	Medicis	NASHA	20 mg/mL, 10,000 particles/mL; BDDE cross-linked; particle size ≈ 1000 μm	6 mos	No	No
Restylane Sub-Q ^a	Medicis	NASHA	1000 particles/mL BDDE cross-linked	6 mos	No	No
Juvéderm Ultra	Allergan	NASHA	24 mg/mL; cross-linked	6–12 mos	No	No
Juvéderm Ultra Plus	Allergan	NASHA	24 mg/mL; cross-linked	6–12 mos	No	No
Hylaform ^b	Allergan	Avian HA		4–6 mos	No	No
Hylaform Plus ^b	Allergan	Avian HA		4–6 mos	No	No
Eleveess	Anika Therapeutics	HA	Cross-linked	No data	No	Yes
Puragen ^a	Mentor	NASHA	20 mg/mL; single cross-linked, additional ester bond	No data	No	Yes
Puragen Plus ^a	Mentor	NASHA	20 mg/mL; single cross-linked, additional ester bond	No data		Yes
Prevelle	Mentor	NASHA	5.5 mg/mL; fully hydrated, not hydrophilic	No data	No	Yes
Prevelle Plus	Mentor	NASHA	5.5 mg/mL; fully hydrated, not hydrophilic	No data	No	Yes
Radiesse	Bioform	Calcium hydroxylapatite	25–45 μm calcium HA microspheres in aqueous polysaccharide gel	Stimulatory: semipermanent	No	No
Sculptra ^c	Sanofi Aventis	PLLA	PLLA hydrogel synthesized from corn	Stimulatory: semipermanent	No	No
ArteFill	Artes Medical	PMMA	20% PMMA (32–40 μm), 80% bovine collagen gel	Permanent	Yes	Yes
Silikon 1000 ^d	Alcon	Polydimethylsiloxane	Highly purified medical grade silicone oil: 1000-cSt	Permanent	No	No
Adatosil 5000 ^d	Bausch & Lomb	Polydimethylsiloxane	Highly purified medical grade silicone oil: 5000-cSt	Permanent		No
Autologous fat		Autologous fat	Transplantation by aspiration and reinjection	Months to years: semipermanent	No	If added by MD

Note: All products are approved by the FDA for cosmetic use as soft tissue filling agents unless otherwise noted.

BDDE, Butanedioldiglycidyl ether; HA, hyaluronic acid; NASHA, nonanimal stabilized hyaluronic acid; PLLA, poly-L-lactic acid; PMMA, polymethylmethacrylate.

^aPending approval by the FDA.

^bHylaform and Hylaform Plus have been phased out by Allergan and have been replaced in their product line by the Juvéderm family of products.

^cSculptra is approved by the FDA for the correction of HIV-associated facial lipoatrophy; it is pending approval for cosmetic use as a soft tissue filler.

^dSilikon 1000 and Adatosil 5000 are both approved by the FDA for use in postoperative tamponade following retinal surgery; their use as soft tissue fillers is "off-label."

ety is 30 mg/mL. Consequently, the manufacturer claims that this higher degree of cross-linking confers longevity with a potential to last up to 1 year. With respect to the lips, Juvéderm's "Hylacross" gel technology gives it a softer, smoother, more natural feel rather than the particulate or granular consistency that can be seen with other HA fillers. Thus, it is an ideal choice for the body of the lip as well as enhancing the vermilion border. Again, sequelae similar to those seen with Restylane (nodule formation if injected too superficially and bluish hue) are possible.

New Fillers

With the cosmetic market changing at lightning speed, it should be no surprise that there are several new nonpermanent fillers on the horizon. While many are approved abroad, there are several that have received recent approval by the FDA or are on the verge of approval. Evolence is a porcine-derived, ribose-cross linked fibrillar type 1 collagen approved in Israel and Europe since 2004 for the correction of contour deficiencies and deformities of soft tissue.²² It is produced by the *in vitro* polymerization of highly purified monomeric porcine collagen, followed by a cross-linking process using natural sugar (glycation). This process extends the life of the filler up to 12 months. One early study showed that Evolence remained stable during 24 months in an animal model as compared with Zyplast and Zyderm, which lost their 3-dimensional shape after 6 months.²³ No pretesting is required because the collagen telopeptides present in the raw material are removed in order to minimize the antigenic potential of the product.²² It has a concentration identical to that of Cosmoplast (35 mg/mL) but, unlike Cosmoplast, there is no lidocaine admixed with the filler. This product, along with its counterpart, Evolence Breeze, is pending approval by the FDA. Evolence Breeze, also 35 mg/mL, is being formulated to have excellent utility in lip augmentation and 1 year longevity.

Eleveess (Anika Therapeutics, Bedford, MA), a new filler, is the first commercially-available HA product to incorporate lidocaine that has been approved by the FDA.²⁴ This feature, along with the fact that it contains the highest concentration of cross-linked HA available in a dermal filler, will likely make it an attractive product for lip enhancement when it becomes available later this year.²⁵ The concept of having lidocaine already premixed into the syringe appears to be a common theme that is popular with other emerging fillers such as Prevelle (recently approved by the FDA) and Puragen (still pending approval by the FDA); both will be distributed by Mentor in the United States.

Semipermanent, Stimulatory Fillers

Semipermanent fillers are stimulatory and consist of Sculptra (poly-L-lactic acid) and Radiesse (calcium hydroxylapatite). Sculptra is a monophasic stimulatory "volumizing" agent that is approved by the FDA for the treatment of HIV-associated facial lipoatrophy and is currently awaiting approval by the FDA for cosmetic use in

the United States.²⁶ It is comprised of tiny particles of poly-L-lactic acid that are diluted in sterile water and stimulate collagen formation once injected into the skin; therefore, dermal thickening and volume augmentation increase over time. The results are not immediate, and a series of 3 or more treatments, each 4 to 8 weeks apart, are usually necessary. When used in the lips, it is associated with nodules and granuloma formation and is thus not recommended for lip augmentation.²⁷ Radiesse, a biphasic stimulatory filler, utilizes calcium hydroxylapatite microspheres suspended in an aqueous carboxymethylcellulose gel carrier. Unlike Sculptra, the gel carrier gives immediate volume correction while the calcium hydroxylapatite microspheres stimulate neocollagenesis for the long-term correction. Its use in the lip is also associated, however, with the potential for nodule formation and it should therefore not be used for augmentation in this area.²⁸

Permanent Fillers

An alternative to a temporary filler is, of course, one that is permanent. In this category, there are 2 main products: ArteFill and liquid silicone. ArteFill, the first permanent biphasic wrinkle filler approved for use in the United States market, is composed of 20% PMMA microspheres suspended in 80% bovine collagen gel admixed with lidocaine. After ArteFill is injected, the collagen degrades over the course of several weeks to months and fibroblasts are stimulated to lay down new collagen around the PMMA microspheres. Similar to the semipermanent fillers Radiesse and Sculptra, there have been reports of nodule and granuloma formation, especially in the setting of immunostimulatory medications such as interferon (often prescribed for hepatitis C).²⁹⁻³² A phenomenon unique to the microimplants is dislocation, a mechanical event, caused by the action of the orbicularis oris muscle, making the implant migrate from where it was originally placed.³² This is obviously more problematic in the setting of permanent fillers, because they will require more invasive interventions for correction rather than just "tincture of time." Furthermore, with aging, there are changes in both hard and soft tissue as well as in self-perception; this necessitates a "tweaking" of the antiaging program, which becomes much more difficult if the previous intervention is permanent.

Liquid silicone, purified polydimethylsiloxane (Silikon), is another popular permanent filler; it was developed for and approved by the FDA for use in the treatment of retinal detachment and is used off-label as a permanent filling agent. It is important to be aware, however, that in some states, such as Nevada, it is illegal to use silicone off-label for cosmetic purposes.

Where it is legal, lip enhancement can be achieved by injecting very small amounts of silicone and strictly adhering to the microdroplet technique.³³⁻³⁴ This technique employs approximately 20 to 25 injections in the lower lip and 15 to 20 injections in the upper lip; the total volume injected in both lips during one

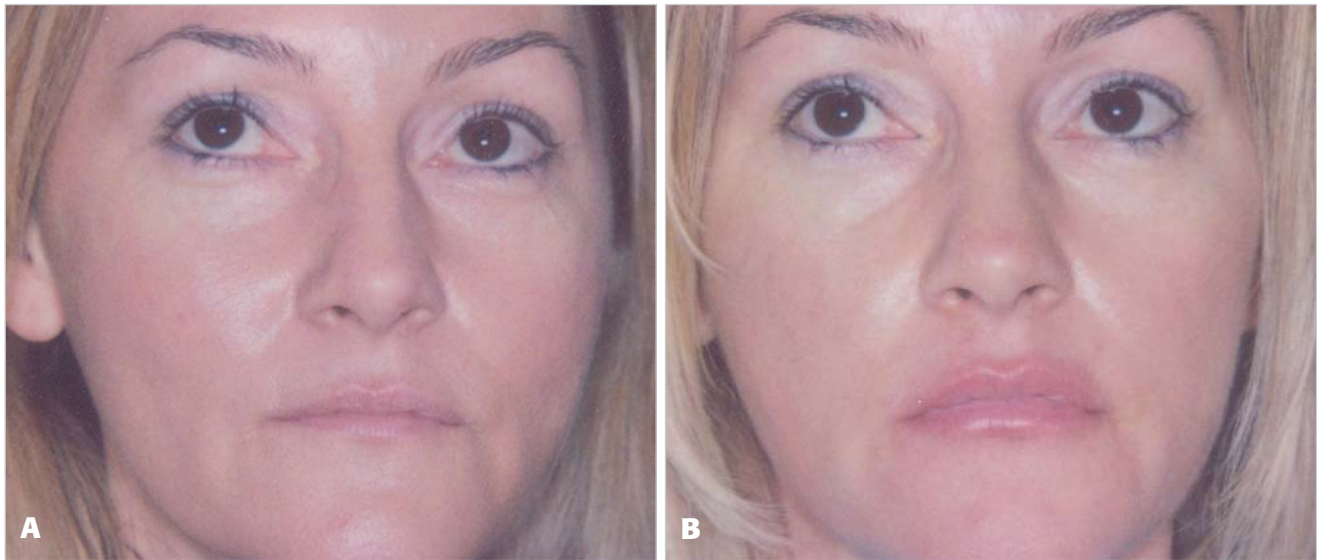

Figure 8. **A,** Pretreatment view of a 39-year-old woman. **B,** Posttreatment view 4 months following lip enhancement with hyaluronic gel.

treatment session usually does not exceed 1.0 mL.³⁴ The microdroplet technique effectively eliminates product migration by the stimulation of a collagen capsule that anchors the microdroplet in place. The augmentation is not caused by the silicone itself, but rather the body's inflammatory response that triggers neocollagenesis.^{33–35} The risk of inflammatory complications increases in patients who have infectious processes, such as sinus or dental infections, in close proximity to injection sites.^{35,36} In addition to local erythema and edema and the formation of nodules and granulomas, more severe complications, including cellulitis, ulcerations, and atypical mycobacterium infections, have been reported.³⁶ Because this is a permanent filler (like ArteFill), it is advisable for the patient to have had previous experience with temporary fillers before definitive treatment with Silik on 1000.

PERMANENT IMPLANTS AND AUTOLOGOUS FAT

Aside from fillers and microimplants, it is important to be aware of other useful products in the cosmetic armamentarium to treat signs of aging in the lips. Surgical implants made of expanded polytetrafluoroethylene (ePTFE), Gore-Tex, W.L. Gore & Associates, Flagstaff, AZ; SoftForm, Tissue Technologies, San Francisco, CA; Ultra-Soft, Tissue Technologies, San Francisco, CA; and Advanta, Atrium Medical Corp., Hudson, NY) and autologous fat can also be used. The benefit of the latter is that it is autologous; the disadvantage is that it is not off-the-shelf and the results are often inconsistent and unpredictable. The side effect profile of the nonbiologic ePTFE implants is similar to that of the permanent fillers; there have been cases of infection, foreign body granulomas, ulceration, and extrusion of these implants from the lips.²⁹ Again, the concern with each of these products is that they are permanent and operator-dependent—once implanted in the lip, they

cannot be removed unless some type of surgical intervention is employed.

CONCLUSIONS

Compared with just a decade ago, there have been many additions to the cosmetic armamentarium of injectable products for lip enhancement. With our current societal interest in maintaining youth and beauty, it is fortunate that there are many more products on the horizon that promise improved results with decreased pain for patients and, in many cases, increased ease of injection for the physician. Therefore, it behooves the physician to gain experience with each product and to master the art of filling the lips. Both the science of the filler (product) and the art of the filler (physician) are critical to an excellent cosmetic result (Figure 8). ▀

DISCLOSURES

Drs. Sarnoff and Gotkin are consultants for Allergan and BioForm Medical. Dr. Saini has no disclosures with regard to the contents of this article.

REFERENCES

1. Mandy S. Art of the lip. *Dermatol Surg* 2007;33:521–522.
2. Klein AW. The art and science of injectable hyaluronic acids. *Plast Reconstr Surg* 2006;117(suppl):35S–37S.
3. Robertson KM, Dyer WK, Dyer 2nd WK. The use of fillers in the aging patient. *Facial Plast Surg* 1996;12:293–301.
4. Maloney BP. Cosmetic surgery of the lips. *Facial Plast Surg* 1996;12:265–278.
5. Klein AW. In search of the perfect lip. *Dermatol Surg* 2005;31:1599–1603.
6. Klein AW. Implantation technique for injectable collagen. *J Am Acad Dermatol* 1983;9:224–228.
7. Baumann L. Cosmoderm/Cosmoplast (human bioengineered collagen) for the aging face. *Facial Plast Surg* 2004;20:125–128.
8. Dover JS, Carruthers A, Carruthers J, Alam M. Clinical use of Restylane. *Skin Therapy Lett* 2005;10:5–7.
9. Perret S, Eble JA, Siljander PR, Merle C, Farndale RW, Theisen M, et al. Prolyl hydroxylation of collagen type 1 is required for efficient binding

- to integrin alpha 1 beta 1 and platelet glycoprotein VI but not to alpha 2 beta 1. *J Biol Chem* 2003;278:29873–29879.
10. Andre P. Hyaluronic acid and its use as a “rejuvenation” agent in cosmetic dermatology. *Semin Cutan Med Surg* 2004;23:218–222.
 11. Jordan D. Soft-tissue fillers for wrinkles, folds and volume augmentation. *Can J Ophthalmol* 2003;38:285–288.
 12. Leonhardt JM, Lawrence N, Narins RS. Angioedema acute hypersensitivity reaction to injectable hyaluronic acid. *Dermatol Surg* 2005;31:577–579.
 13. Fernandez-Acenero MJ, Zamora E, Borbujo J. Granulomatous foreign body reaction against hyaluronic acid: report of a case after lip augmentation. *Dermatol Surg* 2003;29:1225–1226.
 14. Honig JF, Brink U, Korabiowska M. Severe granulomatous allergic tissue reaction after hyaluronic acid injection in the treatment of facial lines and its surgical correction. *J Craniofac Surg* 2003;14:197–200.
 15. Schanz S, Schippert W, Ulmer A, Rassner G, Fierlbeck G. Arterial embolization caused by injection of hyaluronic acid (Restylane). *Br J Dermatol* 2002;146:928–929.
 16. Lowe NJ. Arterial embolization caused by injection of hyaluronic acid (Restylane). *Br J Dermatol* 2003;148:379.
 17. Hirsch RJ, Narurkar V, Carruthers J. Management of injected hyaluronic acid induced Tyndall effects. *Lasers Med Surg* 2006;39:202–204.
 18. Hylaform Plus (package insert). Santa Barbara, CA: Inamed; 2004.
 19. Carruthers J, Carruthers A. Hyaluronic acid gel in skin rejuvenation. *J Drugs Dermatol* 2006;5:959–964.
 20. Raulin C, Greve B, Hartschuh W, Soegding K. Exudative granulomatous reaction to hyaluronic acid (Hylaform). *Contact Dermatitis* 2000;43:178–179.
 21. Monheit GD, Prather CL. Juvéderm: A hyaluronic acid dermal filler. *J Drugs Dermatol* 2007;6:1091–1095.
 22. Smith KC. New fillers for the new man. *Dermatol Ther* 2007;20:388–393.
 23. Pitaru S, Noff M, Blok L, Nir E, Pitaru S, Goldlust A, et al. Long-term efficacy of a novel ribose-cross-linked collagen dermal filler: a histologic and histomorphometric study in an animal model. *Dermatol Surg* 2007;33:1045–1054.
 24. FDA approvals and news. *Skin & Aging* 2007;15:11. (Accessed 7/22/2008, at <http://www.skinandaging.com/article/7423>).
 25. Anika Therapeutics Receives FDA approval for Eleveess Products. Press Release, Woburn, MA. *Cosmetic Dermatology* 2007; 20:590.
 26. FDA approves lipoatrophy filler. *AIDS Patient Care STDS* 2004;18:366–367.
 27. Sherman RN. Sculptra: the new three-dimensional filler. *Clin Plast Surg* 2006;33:539–550.
 28. Jansen DA, Graivier MH. Evaluation of a calcium hydroxylapatite-based implant (Radiesse) for facial soft-tissue augmentation. *Plast Reconstr Surg* 2006;3(Suppl):22S–30S.
 29. Fischer J, Metzler G, Schaller M. Cosmetic permanent fillers for soft tissue augmentation: a new contraindication for interferon therapies. *Arch Dermatol* 2007; 143:507–510.
 30. Reisberger EM, Landthaler M, Wiest L, Schroder J, Stolz W. Foreign body granulomas caused by polymethylmethacrylate microspheres: successful treatment with allopurinol. *Arch Dermatol* 2003;139:17–20.
 31. Hoffmann C, Schuller-Petrovic S, Soyer HP, Kerl H. Adverse reactions after cosmetic lip augmentation with permanent biologically inert implant materials. *J Am Acad Dermatol* 1999;40:100–102.
 32. Lemperle G, Romano JJ, Busso M. Soft tissue augmentation with artecoll: 10-year history, indications, techniques, and complications. *Dermatol Surg* 2003;29:573–587.
 33. Narins R, Beer K. Liquid injectable silicone: a review of its history, immunology, technical considerations, complications, and potential. *Plast Reconstr Surg* 2006;118(Suppl):77S–84S.
 34. Barnett JG, Barnett CR. Silicone augmentation of the lip. *Facial Plast Surg Clin North Am* 2007;15:501–512.
 35. Rapaport M, Vinnik C, Zarem H. Injectable silicone: cause of facial nodules, cellulitis, ulcerations, and migration. *Aesthetic Plast Surg* 1996;20:267–276.
 36. Rees TD, Platt J, Ballantyne Jr DL. An investigation of cutaneous response to dimethylpolysiloxane (silicone liquid) in animals and humans: a preliminary report. *Plast Reconstr Surg* 1965;35:131–139.

Accepted for publication June 30, 2008.

Reprint requests: Deborah S. Sarnoff, MD, 31 Northern Blvd., Greenvale, NY 11548. E-mail: andrew.sarnoff@cosmetiquemd.com.

Copyright © 2008 by The American Society for Aesthetic Plastic Surgery, Inc. 1090-820X/\$34.00

doi:10.1016/j.asj.2008.07.001
